Right Ventricular–Pulmonary Artery Uncoupling in Secondary Tricuspid Regurgitation: Invasive Validation of Echocardiographic Surrogates

Mattia Mercurio, MD, Sergio Caravita, MD, PhD, Denisa Muraru, MD, PhD, Andrea Faini, MSc, PhD, Giovanni Battista Perego, MD, Attilio Iacovoni, MD, Fabio Previdi, MSc, PhD, Michele Senni, MD, Gianfranco Parati, MD, Luigi P. Badano, MD, PhD, and Claudia Baratto, MD, PhD, *Milano, Bergamo, Lombardy, and Bergamo, Italy*

Background: Assessment of right ventricular (RV) function can be challenging in patients with RV volume overload associated with secondary tricuspid regurgitation and heart failure with preserved ejection fraction. We sought to validate echocardiographic metrics that might serve as noninvasive RV–pulmonary artery (PA) coupling surrogates.

Methods: Invasive RV pressure-volume loops were obtained in 16 patients with heart failure, preserved ejection fraction, and at least moderate secondary tricuspid regurgitation. Right ventricular end-systolic elastance (Ees), effective arterial elastance (Ea), tricuspid regurgitation-adjusted Ea (Epa), and related RV-PA coupling indices (Ees/Ea, Ees/Epa) were derived. We explored correlations between RV-PA coupling, hemodynamics, and conventional and 3-dimensional echocardiographic metrics, including forward stroke volume/RV end-systolic volume ratio, effective RV ejection fraction, tricuspid regurgitant volume, and regurgitant fraction.

Results: Right ventricularejection fraction was 61% ± 10%, tricuspid regurgitant volume was 42 (23-59) mL, and regurgitant fraction was 40% ± 19%. The Ea underestimated RV afterload, and Ees/Ea overestimated RV-PA coupling compared with Ees/Epa (0.64 ± 0.24 vs 0.44 ± 0.23, $P < .001$). The value of Ees/Ea correlated with RV ejection fraction ($r = 0.59$; $P = .017$; 95% CI, 0.00, 0.85). The value of Ees/Epa correlated with forward stroke volume/RV end-systolic volume ($\rho = 0.76$; $P < .001$; 95% CI, 0.37, 0.95), effective RV ejection fraction ($r = 0.80$; $P < .001$; 95% CI, 0.54, 0.94), regurgitant volume ($r = -0.67$; $P = .004$; 95% CI, −0.90, –0.57), and regurgitant fraction ($r = -0.77$; $P < .001$; 95% CI, −0.91, –0.50). Conversely, the ratio between tricuspid annular plane systolic excursion and PA systolic pressure was not correlated with either Ees/Ea ($r = 0.03$, $P = .91$) or Ees/Epa ($r = -0.02$, $P = .93$).

Conclusions: In our small cohort of patients with tricuspid regurgitation secondary to heart failure with preserved ejection fraction, RV-PA uncoupling was frequent, underestimated by tricuspid regurgitation–unadjusted metrics, and associated with more impaired hemodynamics. Three-dimensional echocardiography-derived forward stroke volume/RV end-systolic volume, effective RV ejection fraction, tricuspid regurgitant volume, and regurgitant fraction were associated with Ees/Epa, while tricuspid annular plane systolic excursion/PA systolic pressure was not. (J Am Soc Echocardiogr 2026;■:■-■.)

Keywords: Tricuspid regurgitation, Right ventricular function, RV-PA coupling, Pressure-volume loops, Echocardiography

From the Department of Medicine and Surgery, University of Milano-Bicocca, Milano, Italy (D.M., G.P., L.P.B.); Department of Cardiology, Ospedale San Luca IRCCS Istituto Auxologico Italiano, Milano, Italy (M.M., D.M., A.F., G.B.P., G.P., L.P.B., C.B.); Department of Management, Information and Production Engineering, University of Bergamo, Bergamo, Italy (S.C., F.P., C.B.); Department of Cardiology, ASST Papa Giovanni XXIII, Bergamo, Italy (S.C., A.I., M.S.).

Drs. Mercurio and Caravita contributed equally to this work.

Drs. Badano and Baratto contributed equally to this work.

Stephen H. Little, MD, served as guest editor for this report.

This work was funded by the National Plan for NRRP Complementary Investments (PNC, established with the decree law May 6, 2021, no. 59, converted by law no. 101 of 2021) in the call for the funding of research initiatives for technologies and innovative trajectories in the health and care sectors (Directorial Decree no. 931 of 06-06-2022), project no. PNC0000003, Advanced Technologies for Human-Centered Medicine (project acronym: ANTHEM). This paper was also supported by Italian Ministry of Health–Ricerca Finalizzata (grant no. RF-202112374122).

Reprint requests: Luigi P. Badano, MD, PhD, Department of Medicine and Surgery, University of Milano-Bicocca, Piazza dell'Ateneo Nuovo, 1-Milano, Italy (E-mail: *luigi.badano@unimib.it*).

0894-7317

Copyright 2026 The Authors. Published by Elsevier Inc. on behalf of the American Society of Echocardiography. This is an open access article under the CC BY license (http://creativecommons.org/licenses/by/4.0/).

https://doi.org/10.1016/j.echo.2026.07.015



Conductance catheter

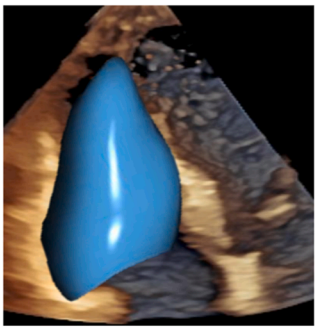



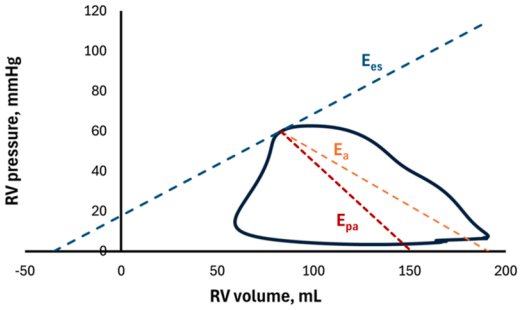

$RVSV_{3DE}$ — RV forward SV_{RHC} = $RegVol_{3DE\text{-}RHC}$

RV forward SV_{RHC}/RV EDV = Effective RVEF

RV forward SV_{RHC}/RV SV_{3DE} = RegFr

RV forward SV_{RHC}/RV ESV

$TAPSE/PASP_{RHC}$

Mercurio. J Am Soc Echocardiogr 2026

Central Illustration Simultaneous RHC with PA and conductance catheters and 3DE to obtain simultaneous standard (Ees/Ea) and forward (Ees/Epa) invasive RV-PA coupling, as well as noninvasive surrogates of RV-PA coupling in patients with moderate to severe TR.

Secondary tricuspid regurgitation (STR) is increasingly recognized as a common and prognostically important complication of heart failure with preserved ejection fraction (EF).[1-3] It arises from a complex interplay of pulmonary vascular loading, right ventricular (RV) remodeling, and functional annular distortion, ultimately leading to progressive RV volume overload.[1,4,5] Although transthoracic echocardiography represents the cornerstone for evaluating STR severity and its hemodynamic consequences, accurate assessment of RV performance in this setting remains challenging.[6-10]

The right ventricle (RV) is uniquely sensitive to changes in preload and afterload.[11,12] In patients with significant STR, chronic regurgitant volume (RegVol) initially leads to adaptive RV dilation to preserve forward stroke volume (SV). However, sustained volume overload eventually increases wall stress, promotes myocardial injury, and contributes to progressive RV dysfunction.[12] Importantly, deterioration may occur despite preserved conventional and advanced indices of RV systolic function, as a result of the unloading effect of significant STR, making early detection of impending decompensation difficult using standard echocardiographic parameters alone.

Within this framework, the concept of RV–pulmonary artery (PA) coupling has emerged as an integrative approach to characterize RV function in relation to its afterload.[13] Right ventricular–PA coupling reflects the balance between RV contractility and pulmonary vascular load, and loss of coupling is a hallmark of reduced RV functional reserve and adverse clinical outcomes. Although invasive pressure-volume loop-derived indices such as end-systolic elastance (Ees) and effective arterial elastance (Ea) represent the gold standard for quantifying coupling, their clinical application is limited by procedural complexity.

To overcome these limitations, several noninvasive echocardiographic surrogates have been proposed.[14-18] Although these indices have been associated with outcomes in several studies, the validity of these parameters in patients with substantial STR remains uncertain, particularly because standard Doppler estimates of PA systolic pressure (PASP) may underestimate the true hemodynamic load imposed on the RV in the presence of regurgitant flow.

Therefore, the present study aimed to validate echocardiographic surrogates of RV-PA coupling against simultaneous invasive RV pressure-volume loop analysis in patients with heart failure and preserved EF and at least moderate STR. By identifying noninvasive indices that more accurately reflect RV-PA coupling in this population, we sought to improve the echocardiographic evaluation of RV functional reserve and facilitate earlier recognition of maladaptive RV remodeling.

METHODS

Study Population

Between January 2023 and April 2025, we prospectively enrolled clinically stable consecutive outpatients undergoing right heart catheterization (RHC) complemented by RV pressure-volume loop analysis. Eligible patients were required to have hemodynamically confirmed heart failure with preserved EF and at least moderate STR.

In the presence of an adequate pretest probability based on clinical history, symptoms, and signs, heart failure with preserved EF was defined by any of the following invasive criteria: PA wedge pressure

Abbreviations

3DE = Three-dimensional echocardiography

Ea = Effective arterial elastance

EDV = End-diastolic volume

Ees = End-systolic elastance

EF = Ejection fraction

Epa = tricuspid regurgitation-adjusted Ea

eRVEF = Effective right ventricular ejection fraction

ESV = End-systolic volume

PA = Pulmonary artery

PASP = Pulmonary artery systolic pressure

RegFr = Regurgitant fraction

RegVol = Regurgitant volume

RHC = Right heart catheterization

RV = Right ventricular, ventricle

STR = Secondary tricuspid regurgitation

SV = Stroke volume

TAPSE = Tricuspid annular plane systolic excursion

TR = Tricuspid regurgitation

> 15 mm Hg at rest, PA wedge pressure > 18 mm Hg during passive leg raise, PA wedge pressure ≥ 25 mm Hg during supine exercise, or an exercise PA wedge pressure/cardiac output slope > 2 mm Hg L^{-1} min^{-1}.[19-22] At least moderate STR was defined according to current quantitative echocardiographic thresholds, including RegVol ≥ 30 mL and/or regurgitant fraction (RegFr) > 15%.[23,24]

Exclusion criteria included left ventricular EF < 50%; hypertrophic, dilated, or infiltrative cardiomyopathies; pericardial disease; pulmonary vascular disease (pulmonary arterial hypertension or chronic thromboembolic pulmonary hypertension); congenital heart disease; at least moderate primary mitral or aortic regurgitation; at least mild mitral or aortic stenosis; primary tricuspid regurgitation (TR) or device-induced TR; clinical instability; and suboptimal pressure-volume loop acquisition.

The study was approved by the local Ethics Committee (5M-2019-23,680,331). Data supporting the findings are available from the corresponding author upon reasonable request (10.5281/zenodo.18175796).

Anthropometric data, demographics, comorbidities, and laboratory values were collected at or before the time of catheterization. Clinical probability of heart failure with preserved EF was assessed using the validated HFpEF-ABA score.[25]

Hemodynamic Protocol and Pressure-Volume Loop Acquisition

All evaluations were performed under local anesthesia, without sedation, and in nonfasting conditions.[26] Patients underwent comprehensive invasive hemodynamic assessment using a PA catheter in conjunction with a high-fidelity conductance catheter for RV pressure-volume loop acquisition (CD Leycom).

Both catheters were inserted percutaneously via ultrasound-guided venous access (right internal jugular or basilic vein) and positioned under fluoroscopic guidance, ensuring optimal signal quality.[27] The radial artery was cannulated with a 3F monitoring catheter under ultrasound guidance. Patients wore a nonrebreathing mask connected to a metabolic cart for breath-by-breath measurement of oxygen consumption, enabling cardiac output determination by the direct Fick method.[28]

At rest, 3-dimensional echocardiography (3DE) was performed simultaneously with invasive hemodynamic evaluation in the supine position.[10] Pressure waveforms and RV pressure-volume loops were continuously recorded using dedicated acquisition software and stored for offline analysis.[27]

Hemodynamic Measurements

Pulmonary artery pressures, PA wedge pressure, and right atrial pressure were measured at end expiration.[29] Cardiac output was calculated using the direct Fick principle, integrating measured oxygen consumption with the arteriovenous oxygen content difference obtained from simultaneous PA and radial artery blood sampling.[28] Forward SV was derived as cardiac output divided by heart rate. Pulmonary vascular resistance and pulmonary arterial compliance were estimated using standard formulas.[30]

Echocardiography

Resting transthoracic echocardiography was performed in the supine position from an apical window by experienced cardiologists using a Vivid E95 ultrasound system (GE Healthcare) equipped with a 4Vc transducer, simultaneously with RHC, as described elsewhere.[10,31] Single-beat full-volume RV 3DE datasets were acquired at a temporal resolution >20 volumes/s. Complete chamber inclusion was verified using a multislice display.[32] Images were digitally stored and analyzed offline using EchoPAC version 204 (GE Healthcare).

Right ventricular end-diastolic volume (EDV), end-systolic volume (ESV), and RV EF were quantified using dedicated software (4D Auto RVQ).The RV SV 3DE was calculated as EDV − ESV, STR RegVol as RV SV 3DE − forward SV, and RegFr as RegVol/RV SV 3DE.[31]

In addition to conventional RV EF calculated as RV SV 3DE/EDV, we calculated indices proposed to better reflect RV function in the presence of significant TR: effective RV EF (eRVEF = forward SV/EDV)[33] and forward SV/RV ESV (Central Illustration).[34] Tricuspid annular plane systolic excursion (TAPSE) was also measured using M-mode echocardiography[35] and was combined with PASP obtained invasively to derive TAPSE/PASP RHC (Central Illustration).

Pressure-Volume Loop Analysis

For each patient, conductance-derived RV volume signals were calibrated using RV EDV and ESV obtained by 3DE (Central Illustration). During offline postprocessing, at least 5 representative stable beats were selected at end expiration to minimize respiratory influences.

Several methods have been proposed to calculate Ees from RV pressure curves.[36,37] In this study we relied on the original single-beat method proposed by Brimioulle *et al.*[36] In this approach, the isovolumic contraction and relaxation phases of the RV pressure waveform are identified using the first derivative of pressure (dP/dt), and the theoretical maximal isovolumic pressure is estimated by sinusoidal interpolation of these segments. End-systolic elastance was then calculated as Ees = (theoretical maximal isovolumic pressure − RV end-systolic pressure)/RV SV.

Right ventricular end-systolic pressure and SV were automatically derived by Conduct NT software (CD Leycom) from calibrated pressure-volume tracings; Ea was calculated as Ea = RV end-systolic pressure/RV SV. Standard RV-PA coupling was expressed as Ees/Ea (Central Illustration).[27]

HIGHLIGHTS

- TR-unadjusted metrics underestimate both invasive and noninvasive RV-PA coupling.
- In patients with significant TR, the ratio TAPSE/PASP is not associated with Ees/Epa.
- 3DE-derived metrics of RV-PA coupling are associated with Ees/Epa.

Because conventional Ea may underestimate RV afterload in STR due to regurgitant flow into the right atrium, tricuspid regurgitation-adjusted Ea (Epa) was computed as an alternative index of forward afterload: Epa = RV end-systolic pressure/forward SV.[38] Forward RV-PA coupling was then expressed as Ees/Epa, isolating the effective volume ejected into the pulmonary circulation and excluding regurgitant flow (Central Illustration).[38]

STATISTICS

Data are presented as mean ± SD or median [first; third quartile] for continuous variables and as number (%) for discrete variables. Comparisons between Ea and Epa and between Ees/Ea and Ees/Epa were performed with paired *t* test or Wilcoxon test, as appropriate. Correlation analyses were assessed using Pearson or Spearman tests depending on data distribution, and linear regression was performed to assess relevant associations. We then explored the relationships between invasive RV-PA coupling indices (Ees/Ea and Ees/Epa) and (1) hemodynamic parameters indicative of RV function (right atrial pressure, cardiac output, SV, mixed oxygen venous saturation); (2) STR severity (RegVol and RegFr); and (3) proposed noninvasive surrogates of RV-PA coupling (forward SV/ESV, eRVEF, TAPSE/PASP RHC). Given the exploratory nature of the study and the limited sample size, only univariate regression analyses were performed, and no multivariable models were fitted.

RESULTS

Study Population

Sixteen patients with hemodynamically confirmed heart failure with preserved EF and moderate ($n = 11$) or severe STR underwent RHC with pressure-volume analysis and simultaneous 3DE. The baseline clinical and echocardiographic characteristics of the cohort are summarized in Table 1. Effective pulmonary arterial elastance was higher than Ea ($P < .001$, Figure 1), reflecting the underestimation of RV afterload when RegVol is not accounted for. Accordingly, RegVol-corrected RV-PAcoupling (Ees/Epa) was significantly lower than conventional coupling (Ees/Ea; 0.44 ± 0.23 vs 0.64 ± 0.24; $P < .001$; Figure 1). Exemplificative pressure-volume loops from our patients are reported both in the Central Illustration and in Figure 1.

Table 1 Demographic and clinical characteristics of the study population

General characteristics	Whole cohort ($n = 16$)
Age, years	78 ± 7
Sex, female, *n* (%)	11 (69)
Body mass index, kg/m^2	25.9 ± 3.7
Pacemaker, *n* (%)	5 (31)
Atrial fibrillation, *n* (%)	12 (75)
HFpEF-ABA probability, %	92 [71-95]
Blood tests:	
BNP, pg/mL	348 ± 187
NT-proBNP, pg/mL	1,465 [559-2,291]
Hemoglobin, g/dL	12.8 ± 1.48
Medical therapy:	
Angiotensin-converting enzyme inhibitor/ angiotensin receptor blocker, *n* (%)	9 (56)
Beta-blocker	11 (69)
Calcium channel blocker, *n* (%)	3 (19)
Mineralocorticoid receptor antagonist, *n* (%)	8 (50)
SGLT2 inhibitor, *n* (%)	5 (31)
Loop diuretic, *n* (%)	14 (88)
Furosemide equivalent dose, mg/day	50 [25-62.5]
Echocardiography:	
RV EDV, mL/m^2	88 [81-129]
RV ESV, mL/m^2	35 [27-61]
RV EF, %	61 ± 10
TR RegVol, mL	42 [23-59]
TR RegFr, %	40 ± 19
Hemodynamics:	
Heart rate, bpm	68 ± 12
Systolic blood pressure, mm Hg	146 ± 28
Diastolic blood pressure, mm Hg	63 [60-76]
Mean PA pressure, mm Hg	30 ± 5
PA wedge pressure, mm Hg	22 ± 5
Right atrial pressure, mm Hg	12 ± 5
Cardiac index, L/min/m^2	2.44 ± 0.9
SV index, mL/m^2	37 ± 14
Pulmonary vascular resistance, WU	2.0 ± 1.3
PA Compliance, mL/mm Hg	3.2 ± 1.4
Pressure-volume loop variables:	
Ees	0.27 ± 0.15
Ea	0.41 ± 0.17
Epa	0.61 [0.37-0.87]
Ventricular-arterial coupling (Ees/Ea)	0.64 ± 0.24
Ventricular-PA coupling (Ees/Epa)	0.44 ± 0.23

BNP, B-type natriuretic peptide; *NT-ProBNP*, N-terminal pro-B-type natriuretic peptide.

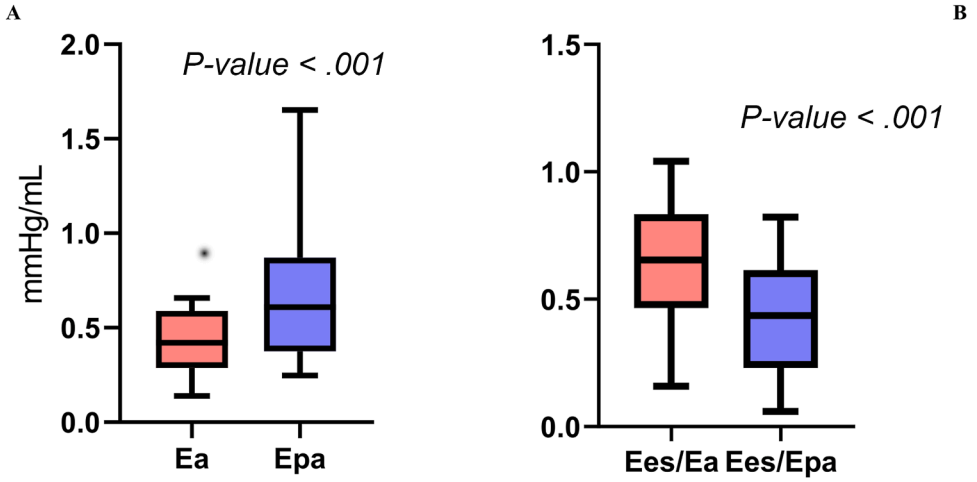

Figure 1 Pulmonary artery elastance **(A)** and RV-PA coupling **(B)**. The *red bars* show the values obtained with the standard measurements. The *blue bars* show the values obtained after correcting Ea for the tricuspid RegVol.

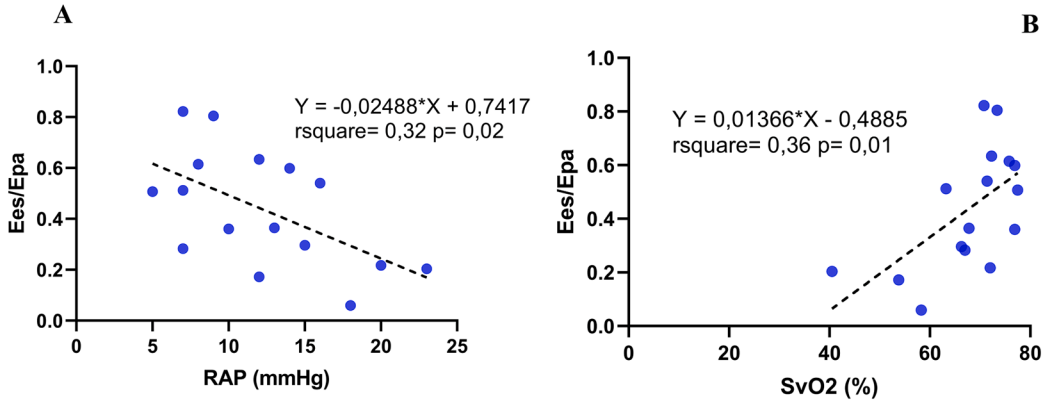

Figure 2 Linear regression between the effective (forward) ventricular-arterial coupling, right atrial pressure, and mixed venous oxygen saturation. *RAP,* Right atrial pressure; *SvO_2,* mixed venous oxygen saturation.

Association between Invasive RV-PA Coupling and Hemodynamics

At rest, RegVol-corrected RV-PA coupling (Ees/Epa) but not conventional Ees/Ea was significantly associated with indices of systemic congestion and impaired oxygen delivery. Specifically, Ees/Epa demonstrated an inverse correlation with right atrial pressure ($r = -0.57$; $P = .022$; 95% CI, −0.79, −0.20) and a positive association with mixed venous oxygen saturation ($\rho = 0.59$; $P = .017$; 95% CI, 0.06, 0.83). In univariate linear regression analyses, Ees/Epa was associated with higher right atrial pressure ($\beta = -0.025$, $R^2 = 0.32$, $P < .02$) and lower mixed venous oxygen saturation ($\beta = 0.014$, $R^2 = 0.36$; Figure 2). Neither Ees/Ea nor Ees/Epa turned out to be significantly correlated with cardiac output or forward SV.

Relationship between RV-PA Coupling and STR Severity

Secondary TR severity was closely related to invasive measures of RV-PA uncoupling. Regurgitant volume correlated inversely with both coupling indices, with a stronger association observed for Ees/Epa (Pearson $r = -0.67$; $P = .004$; 95% CI, −0.90, −0.57) than for Ees/Ea (Spearman $\rho = -0.63$; $P = .009$; 95% CI, −0.82, −0.23). In univariate regression analysis, RegVol significantly explained variability in Ees/Epa ($\beta = -0.004$, $R^2 = 0.45$, $P < .01$), whereas the association with Ees/Ea did not reach statistical significance ($\beta = -0.003$, $R^2 = 0.23$, $P = .06$; Figure 3).

Regurgitant fraction showed an even more robust inverse relationship with invasive coupling indices, particularly for Ees/Epa ($r = -0.77$; $P < .001$; 95% CI, −0.91, −0.50), accounting for nearly 60% of its variability ($\beta = -0.0092$, $R^2 = 0.60$). In contrast, the correlation with Ees/Ea was more modest ($r = -0.53$; $P = .036$; 95% CI, −0.83, −0.11; $\beta = -0.0066$, $R^2 = 0.28$; Figure 4). No correlation was found between RV-PA coupling (Ees/Ea or Ees/Epa) and natriuretic peptides.

Correlations between Invasive Coupling Indices and Echocardiographic Surrogates

Among the echocardiographic indices proposed as surrogates of RV-PA coupling, forward flow–based parameters demonstrated the strongest associations with invasive measurements.

The ratio forward SV/ESV correlated significantly with both Ees/Ea and Ees/Epa, with a stronger relationship for Ees/Epa ($\rho = 0.76$; $P < .001$; 95% CI, 0.37, 0.95; $\beta = 0.173$; $R^2 = 0.43$; $P < .01$) than

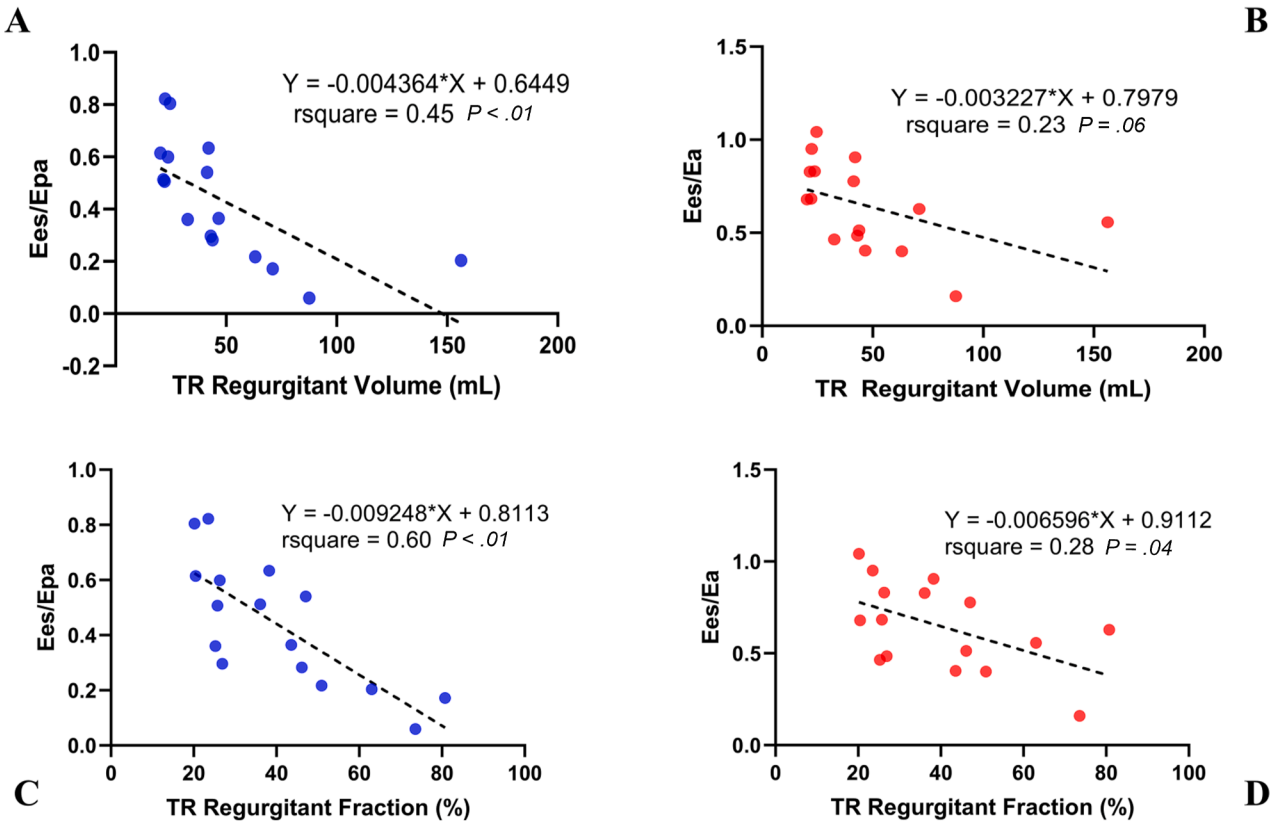

Figure 3 Linear regression between RV-PA coupling and metrics of TR severity. The *red dots* show the values obtained with the standard measurements. The *blue dots* show the values obtained after correcting Ea for the tricuspid RegVol.

for Ees/Ea ($\rho = 0.62$; $P = .011$; 95% CI, 0.14, 0.89; $\beta = 0.163$; $R^2 = 0.34$; $P = .02$; Figure 4).

Similarly, eRVEF showed a strong correlation with Ees/Epa ($r = 0.80$; $P < .001$; 95% CI, 0.54, 0.94), explaining nearly two-thirds of its variability ($\beta = 0.01232$, $R^2 = 0.64$). The association with Ees/Ea was more moderate ($r = 0.63$; $P < .01$; 95% CI, 0.16, 0.86; $\beta = 1.007$; $R^2 = 0.39$; Figure 4).

Conventional RV EF correlated with Ees/Ea ($r = 0.59$; $P = .017$; 95% CI, 0.00, 0.85) but did not show a statistically significant association with Ees/Epa ($r = 0.46$; $P = .076$; 95% CI, −0.19, 0.84), suggesting reduced sensitivity in the presence of volume overload.

Notably, TAPSE/PASP RHC did not correlate with either invasive coupling indices (Ees/Ea: $r = 0.03$, $P = .91$; Ees/Epa: $r = -0.02$, $P = .93$), indicating the limited utility of this commonly used metric in patients with significant STR, even though PASP was invasively measured. The TAPSE/PASP RHC was associated with Ea and Epa (Table 1).

DISCUSSION

In this study, we employed invasive RV pressure-volume loops to characterize RV-PA coupling in patients with heart failure with preserved EF and at least moderate STR. The main findings can be summarized as follows: (1) patients with heart failure with preserved EF and significant STR exhibit markedly impaired RV-PA coupling despite preserved RV EF; (2) failure to account for RegVol leads to underestimation of RV afterload and overestimation of RV-PA coupling; (3) RegVol-corrected coupling (Ees/Epa), rather than Ees/Ea, is more closely associated with physiological markers of right heart efficiency; (4) forward flow–based 3DE indices, including eRVEF and forward SV/ESV, correlate strongly with invasive coupling, whereas TAPSE/PASP does not; (5) STR severity emerges as a major determinant of RV-PA uncoupling, underscoring the advanced disease profile of heart failure with preserved EF patients with significant STR.

Collectively, these findings highlight the limitations of conventional RV systolic indices in the setting of RegVol and support the use of coupling metrics that incorporate forward flow when assessing RV functional reserve in STR.

Adjusting RV-PA Coupling for TR Severity

The concept that TR alters RV afterload assessment has been previously reported by Yoshida *et al.*,[38,39] who demonstrated that even pressure-volume-loop-derived coupling may be overestimated when significant STR is present. In this context, backward systolic flow into the right atrium represents a parallel, low-resistance pathway that reduces the effective forward SV delivered to the pulmonary circulation. Because conventional Ea incorporates RV SV (which includes the RegVol), it may substantially underestimate the true afterload opposing forward ejection. Consequently, Ees/Ea can appear artificially preserved even in the presence of impaired contractility.

To address this limitation, pulmonary arterial elastance adjusted for forward SV (Epa) has been proposed as a more physiologically appropriate measure of effective RV afterload in STR.[38,39] This approach

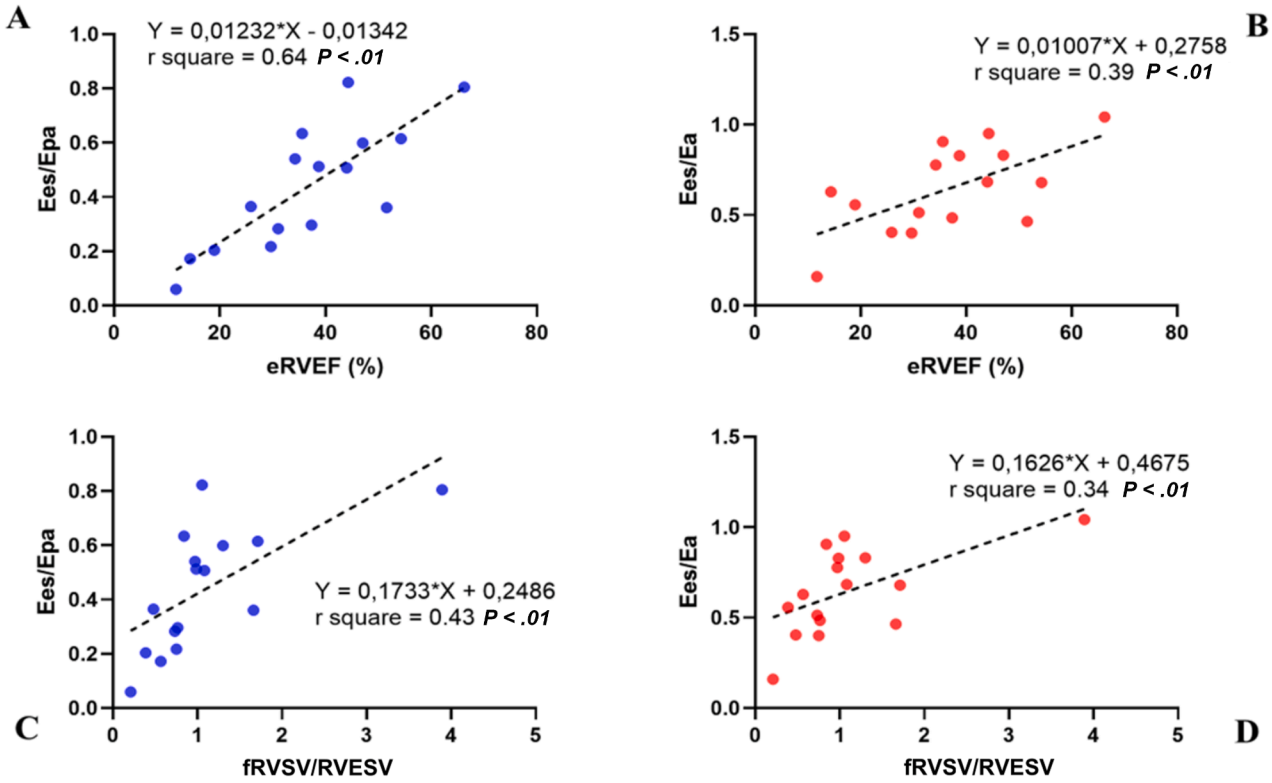

Figure 4 Linear regression between RV-PA coupling and surrogate indices of coupling obtainable through 3DE. The *red dots* show the values obtained with the standard measurements. The *blue dots* show the values obtained after correcting Ea for the tricuspid RegVol.

yields a RegVol-adjusted coupling index (Ees/Epa) that better reflects the interaction between RV contractility and pulmonary vascular load when RegVol is significant.

In our cohort, Epa was significantly higher than Ea, confirming that RV afterload is underestimated when RegVol is not taken into account. Moreover, coupling values were significantly reduced, with Ees/Ea already below the theoretical uncoupling threshold (<1) and Ees/Epa demonstrating even more pronounced impairment. Importantly, these abnormalities occurred despite preserved 3DE-derived RV EF, reinforcing the concept that TR-related unloading masks early RV dysfunction and that coupling analysis may provide a more sensitive marker of maladaptive remodeling in heart failure with preserved EF and STR.

Hemodynamic Significance of STR-Adjusted Coupling

Beyond its physiological plausibility, Ees/Epa showed stronger associations with clinically meaningful hemodynamic correlates than Ees/Ea. The inverse relationship between Ees/Epa and right atrial pressure suggests that patients with better preserved RV-PA coupling can maintain lower systemic venous congestion.

Similarly, the positive association with mixed venous oxygen saturation indicates that preserved coupling supports adequate forward flow and systemic oxygen delivery. Mixed oxygen venous saturation provides an integrated marker of the balance between cardiac output and metabolic demand, and its relationship with Ees/Epa further supports the clinical relevance of RegVol-adjusted coupling as a marker of right heart efficiency in STR.

Echocardiographic Surrogates of RV-PA Coupling

Given the complexity and invasiveness of pressure-volume loop assessment, several imaging surrogate parameters have been proposed to estimate RV-PA coupling noninvasively.[7] Ratios such as TAPSE/PASP or RV free-wall strain/PASP are attractive because of their simplicity and feasibility and have been associated with outcomes in both medically and transcatheter-treated STR cohorts.[14-16,18] However, these indices remain imperfect surrogates of true coupling.

Tricuspid annular plane systolic excursion and RV free-wall longitudinal strain reflect only a single component of RV contraction, are load dependent, and do not capture circumferential or outflow tract mechanics. Therefore, they cannot be equated to RV contractility (Ees). Furthermore, the Doppler estimate of PASP is itself sensitive to measurement error, particularly in severe TR, where Doppler gradients and right atrial pressure estimate may be unreliable.[40] Additionally, these ratios combine variables that are not linearly related to elastance and can propagate errors due to their mutual and independent load dependence. These limitations likely explain why TAPSE/PASP did not correlate with either invasive coupling index in our study. The TAPSE/PASP ratio was associated with Ea and Epa, likely because of the collinearity between PASP and Ea as well as Epa.

In contrast, forward flow–based indices derived from 3DE provide a more comprehensive assessment of global RV chamber performance and avoid dependence on Doppler PASP estimation. Notably both eRVEF and forward SV/ESV correlated strongly with Ees/Epa, supporting their role as meaningful bedside surrogates of RV-PA coupling in

STR. These parameters incorporate forward flow and regurgitant burden, addressing the key physiological distortion introduced by TR.

Conversely, conventional RV EF correlated more closely with Ees/Ea than with Ees/Epa, further confirming its load dependency and limited ability to reflect true contractile-afterload interaction in patients with significant STR.

LIMITATIONS

This study has several limitations. First, the sample size was relatively small, which may limit statistical power and generalizability. Nonetheless, simultaneous 3DE and invasive acquisition of RV pressure-volume loops in STR remains technically demanding, and the observed associations were consistent across multiple physiologically relevant variables.

Second, we estimated Ees using the validated single-beat method rather than the multibeat preload reduction approach. Although multibeat analysis remains the gold standard, it would require femoral venous access and transient preload manipulation, creating discomfort for patients and reducing feasibility in this clinical setting. Furthermore, more recent refinements of the single-beat method have been proposed to improve reproducibility of theoretical maximal isovolumic pressure estimation.[37,41] These approaches were not evaluated in the present study, favoring the original method,[36] and warrant investigation in future studies.

Due to the small sample size and high prevalence of Ees/Ea $<$ 0.805,[42] we could not derive meaningful thresholds of noninvasive surrogates for RV-PA uncoupling in patients with heart failure with preserved EF and STR. Nonetheless, our exploratory work intended to verify a correlation between noninvasive surrogates and invasive metrics of RV-PA coupling. We could not test other presumed noninvasive surrogates of RV-PA coupling such as those derived from RV free-wall strain or RV fractional area change, limiting our analysis to simple standard surrogates for RV-PA coupling (TAPSE/PASP)[14,43] and advanced 3DE-based metrics.[33,34] Since only a minority of patients had data on kidney and liver blood biomarkers, we could not test the association between the formers (both kidney and liver biomarkers) and RV-PA coupling. Finally, the prognostic impact of RV-PA coupling was not assessed.

CONCLUSION

In our small cohort of patients with heart failure and preserved EF and significant STR, RV-PA uncoupling was commonly observed despite preserved RV pump function. Accounting for STR severity might be relevant, as RegVol-adjusted coupling (Ees/Epa) may more accurately reflect RV afterload and may relate more closely to hemodynamic markers of right heart efficiency.

Forward flow–based 3DE indices, such as eRVEF and forward SV/RV ESV, represent promising noninvasive surrogates of RV-PA coupling in this population, whereas TAPSE/PASP might not reliably capture coupling status in the presence of significant STR.

REVIEW STATEMENT

Given her role as *JASE* Editor-in-Chief, Patricia A. Pellikka, MD, and given his role as *JASE* Associate Editor, Luigi P. Badano, MD, PhD, had no involvement in the peer review of this article and have no access to information regarding its peer review. Full responsibility for the editorial process for this article was delegated to guest editor Stephen H. Little, MD.

CONFLICTS OF INTEREST

S.C. has received consultancy fees from Alleviant, Janssen, MSD, and Tenax Therapeutics. The remaining authors have nothing to disclose.

ACKNOWLEDGMENTS

We thank the nurses of the cardiac catheterization laboratory, Ospedale San Luca IRCCS Istituto Auxologico Italiano, for their invaluable support in performing exercise hemodynamic tests, including Francesca Boniolo, Pierpaolo Di Pierro, Giuseppe Di Stasio, Marta Maria Fasano, Andrea Fiorentini, Annalisa Friggi, Cesare Longo, Jana Quario Rondo, and Marco Setti. The authors are grateful to Laboratori Guidotti S.p.A. for providing software for echocardiographic analysis free of charge.

SUPPLEMENTARY DATA

Supplementary data related to this article can be found at https://doi.org/10.1016/j.echo.2026.07.015.

REFERENCES

1. Hahn RT, Lindenfeld J, Bohm M, et al. Tricuspid regurgitation in patients with heart failure and preserved ejection fraction: JACC state-of-the-art Review. J Am Coll Cardiol 2024;84:195-212.
2. Harada T, Obokata M, Omote K, et al. Functional tricuspid regurgitation and right atrial remodeling in heart failure with preserved ejection fraction. Am J Cardiol 2022;162:129-35.
3. Naser JA, Harada T, Reddy YN, et al. Prevalence of HFpEF in isolated severe secondary tricuspid regurgitation. JAMA Cardiol 2025;10:182-7.
4. Adamo M, Chioncel O, Pagnesi M, et al. Epidemiology, pathophysiology, diagnosis and management of chronic right-sided heart failure and tricuspid regurgitation. A clinical consensus statement of the Heart Failure Association (HFA) and the European Association of Percutaneous Cardiovascular Interventions (EAPCI) of the ESC. Eur J Heart Fail 2024;26:18-33.
5. Obokata M, Reddy YNV, Melenovsky V, et al. Deterioration in right ventricular structure and function over time in patients with heart failure and preserved ejection fraction. Eur Heart J 2019;40:689-97.
6. Badano LP, Tomaselli M, Muraru D, et al. Advances in the assessment of patients with tricuspid regurgitation: a state-of-the-art review on the echocardiographic evaluation before and after tricuspid valve interventions. J Am Soc Echocadiogr 2024;37:1083-102.
7. Hahn RT, Badano L, Praz F, et al. The last decade in tricuspid regurgitation: how imaging shaped a field. JACC Cardiovasc Imaging 2025;18:1013-41.
8. Hahn RT, Badano LP, Bartko PE, et al. Tricuspid regurgitation: recent advances in understanding pathophysiology, severity grading and outcome. Eur Heart J Cardiovasc Imaging 2022;23:913-29.
9. Tomaselli M, Penso M, Badano LP, et al. Right ventricular function and outcomes stratified by the effective regurgitant orifice area in secondary tricuspid regurgitation. Can J Cardiol 2025;41:1185-94.
10. Caravita S, Liberatore M, Badano LP, et al. Determinants of right heart hemodynamic derangement in patients with and without tricuspid regurgitation. Circ Heart failure 2025;18:e012813.

11. Sanz J, Sanchez-Quintana D, Bossone E, et al. Anatomy, function, and dysfunction of the right ventricle: JACC state-of-the-art review. J Am Coll Cardiol 2019;73:1463-82.
12. Naeije R, Tello K, D'Alto M. Tricuspid regurgitation: right ventricular volume versus pressure load. Curr Heart Fail Rep 2023;20:208-17.
13. Wu Z, Xie M, Zhang L, et al. Prognostic implication of right ventricular-pulmonary artery coupling in valvular heart disease. Front Cardiovasc Med 2024;11:1504063.
14. Fortuni F, Butcher SC, Dietz MF, et al. Right ventricular-pulmonary arterial coupling in secondary tricuspid regurgitation. Am J Cardiol 2021;148:138-45.
15. Prihadi EA, van der Bijl P, Dietz M, et al. Prognostic implications of right ventricular free wall longitudinal strain in patients with significant functional tricuspid regurgitation. Circ Cardiovasc imaging 2019;12:e008666.
16. Lurz P, Orban M, Besler C, et al. Clinical characteristics, diagnosis, and risk stratification of pulmonary hypertension in severe tricuspid regurgitation and implications for transcatheter tricuspid valve repair. Eur Heart J 2020;41:2785-95.
17. Stolz L, Weckbach LT, Karam N, et al. Invasive right ventricular to pulmonary artery coupling in patients undergoing transcatheter edge-to-edge tricuspid valve repair. JACC Cardiovasc Imaging 2023;16:564-6.
18. Brener MI, Lurz P, Hausleiter J, et al. Right ventricular-pulmonary arterial coupling and afterload reserve in patients undergoing transcatheter tricuspid valve repair. J Am Coll Cardiol 2022;79:448-61.
19. Fudim M, Kittipibul V, Swavely A, et al. Discrepancy in the diagnosis of heart failure with preserved ejection fraction between supine versus upright exercise hemodynamic testing. Circ Heart Fail 2024;17:e012020.
20. Baratto C, Caravita S, Soranna D, et al. Exercise haemodynamics in heart failure with preserved ejection fraction: a systematic review and meta-analysis. ESC Heart Fail 2022;9:3079-91.
21. Baratto C, Caravita S, Soranna D, et al. Current limitations of invasive exercise hemodynamics for the diagnosis of heart failure with preserved ejection fraction. Circ Heart Fail 2021;14:e007555.
22. Baratto C, Minari S, Rao VN, et al. Diagnostic performance of passive leg-raise and low-workload exercise to diagnose heart failure with preserved ejection fraction. J Card Fail 2025;31:1675-83.
23. Zoghbi WA, Adams D, Bonow RO, et al. Recommendations for noninvasive evaluation of native valvular regurgitation: a report from the American Society of Echocardiography developed in collaboration with the Society for Cardiovascular Magnetic Resonance. J Am Soc Echocadiogr 2017;30:303-71.
24. Lancellotti P, Pibarot P, Chambers J, et al. Multi-modality imaging assessment of native valvular regurgitation: an EACVI and ESC council of valvular heart disease position paper. Eur Heart J Cardiovasc Imaging 2022;23:e171-232.
25. Reddy YNV, Carter RE, Sundaram V, et al. An evidence-based screening tool for heart failure with preserved ejection fraction: the HFpEF-ABA score. Nat Med 2024;30:2258-64.
26. Godino C, Sisinni A, Raone L, et al. Hemodynamic right heart catheterization before transcatheter mitral and tricuspid therapies. Circ Heart Fail 2025;18:e012489.
27. Brener MI, Masoumi A, Ng VG, et al. Invasive right ventricular pressure-volume analysis: basic principles, clinical applications, and practical recommendations. Circ Heart Fail 2022;15:e009101.
28. Caravita S, Baratto C, Filippo A, et al. Shedding light on latent pulmonary vascular Ddsease in heart failure with preserved ejection fraction. JACC Heart Fail 2023;11:1427-38.
29. Baratto C, Faini A, Gallone GP, et al. Pulmonary artery wedge pressure and left ventricular end- diastolic pressure during exercise in patients with dyspnoea. ERJ Open Res 2023;9:00750-2022.
30. Caravita S, Faini A, Carolino D, Araujo S, et al. Clinical phenotypes and outcomes of pulmonary hypertension due to left heart disease: role of the pre-capillary component. PLoS One 2018;13:e0199164.
31. Badano LP, Baratto C, Liberatore M, et al. Invasive validation of right ventricular stroke volume and tricuspid regurgitant volume obtained from three-dimensional echocardiography. J Am Soc Echocardiogr 2026;39:333-41.
32. Lang RM, Badano LP, Tsang W, et al. EAE/ASE recommendations for image acquisition and display using three-dimensional echocardiography. Eur Heart J Cardiovasc Imaging 2012;13:1-46.
33. Clement A, Tomaselli M, Badano L, et al. Association with outcome of the regurgitant-volume adjusted right ventricular ejection fraction in secondary tricuspid regurgitation. J Am Soc Echocardiogr 2024;38:451-64.
34. Gavazzoni M, Badano LP, Cascella A, et al. Clinical value of a novel three-dimensional echocardiography-derived index of right ventricle-pulmonary artery coupling in tricuspid regurgitation. J Am Soc Echocardiogr 2023;36:1154-66.e3.
35. Mukherjee M, Rudski LG, Addetia K, et al. Guidelines for the echocardiographic assessment of the right heart in adults and special considerations in pulmonary hypertension: recommendations from the American Society of Echocardiography. J Am Soc Echocardiog 2025;38:141-86.
36. Brimioulle S, Wauthy P, Ewalenko P, et al. Single-beat estimation of right ventricular end-systolic pressure-volume relationship. Am J Physiol Heart Circ Physiol 2003;284:H1625-30.
37. Bellofiore A, Vanderpool R, Brewis MJ, et al. A novel single-beat approach to assess right ventricular systolic function. J Appl Physiol (1985) 2018;124:283-90.
38. Yoshida K, van Wezenbeek J, Wessels JN, et al. Tricuspid regurgitation in pulmonary arterial hypertension: a right ventricular volumetric and functional analysis. Eur Respir J 2024;63:2301696.
39. Yoshida K, Axelsen JB, Saku K, et al. How to incorporate tricuspid regurgitation in right ventricular- pulmonary arterial coupling. J Appl Physiol (1985) 2023;135:53-9.
40. Sugiura A, Tanaka T, Kavsur R, et al. Refining accuracy of RV-PA coupling in patients undergoing transcatheter tricuspid valve treatment. Clin Res Cardiol 2024;113:177-86.
41. Moon GS, Scheel PJ 3rd, Montovano M, et al. A Novel computational pipeline for acquiring pressure-volume hemodynamics of the right ventricle in pulmonary hypertension. JACC Heart Fail 2026;14:102753.
42. Tello K, Wan J, Dalmer A, et al. Validation of the tricuspid annular plane systolic excursion/systolic pulmonary artery pressure ratio for the assessment of right ventricular-arterial coupling in severe pulmonary hypertension. Circ Cardiovasc Imaging 2019;12:e00947.
43. Delgado V, Fortuni F. Right ventricular-pulmonary artery coupling in tricuspid transcatheter edge-to-edge repair: suitability or risk stratification? JACC Cardiovasc Interv 2025;11:1422-4.